

## Case Report

### Correspondence

Shaukat Bilal  
sb72pk@yahoo.com

Received 15 April 2010  
Accepted 2 August 2010

# Human bovine tuberculosis – remains in the differential

Shaukat Bilal,<sup>1</sup> Mudassir Iqbal,<sup>2</sup> Philip Murphy<sup>3</sup> and Joan Power<sup>1</sup>

<sup>1</sup>Department of Respiratory Medicine, Naas General Hospital, Trinity College Dublin, Kildare, Ireland

<sup>2</sup>Department of Neurology, Adelaide and Meath Hospital, Trinity College Dublin, Dublin 24, Ireland

<sup>3</sup>Department of Microbiology, Adelaide and Meath Hospital, Trinity College Dublin, Dublin 24, Ireland

*Mycobacterium bovis* is a pathogen of cattle. The unpasteurized milk of affected cattle is a source of infection in humans. Despite the screening of cattle and the pasteurization of milk, *M bovis* has not been eradicated. A high index of clinical suspicion is needed in symptomatic patients with a history of possible exposure. At risk groups include animal workers, farmers, meat packers, vets and zoo keepers. Humans are usually infected by the aerosol route. We present two cases of human bovine tuberculosis. One was a presumptive case and the second was a confirmed case. Both responded well to antituberculous therapy. In the confirmed case, there was evidence of transmission to the partner living in the same house. Rifampicin prophylaxis was given to the exposed case. The *M. bovis* from the confirmed case was isoniazid resistant, in addition to having the well known resistance to pyrazinamide. Isoniazid resistance has been described before in those who are immunocompromised. We describe it in an immunocompetent patient.

## Case reports

### Case 1

A 50-year-old male farm worker presented to our clinic in July 2008 with a history of tightness of the chest, dyspnoea and erythema nodosum in March of the same year. His antistreptolysin O titre was elevated at that time at 545 IU ml<sup>-1</sup>. There was no history of night sweats, weight loss, cough or constitutional symptoms. In the family history, his sister had erythema nodosum during her pregnancy. He was a welder by occupation. His past medical history included childhood asthma and allergic rhinitis. On examination, his temperature was 36.5°C, his blood pressure 125/73 mmHg, pulse 66 beats min<sup>-1</sup> and oxygen saturation was 96% on ambient air. His cardiovascular system was normal, a respiratory examination was unremarkable and his abdomen was soft and non-tender. There was no cervical and axillary lymph node enlargement. Leg examination revealed red healing macules on the anterior aspect of both shins associated with some dry skin and scaling. There was no pitting oedema.

Laboratory examination showed a normal full blood count with an erythrocyte sedimentation rate of 15 mm h<sup>-1</sup>. The patient's serum IgE level was elevated at 1000 IU l<sup>-1</sup>. However, other immunoglobulins showed a normal level.

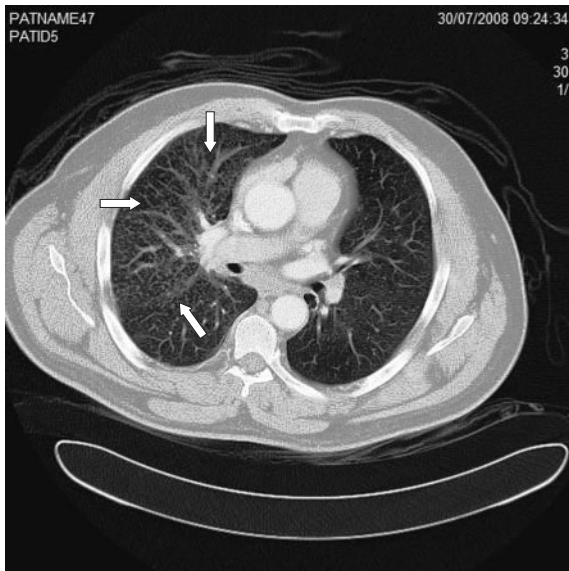
Abbreviations: ATT, antituberculous therapy; bTB, bovine tuberculosis; CT, computed tomography; HIV, human immunodeficiency virus; TB, tuberculosis.

His serum angiotensin converting enzyme level was normal and a repeat antistreptolysin O titre was normal. His human immunodeficiency virus (HIV) status was not tested in view of lack of risk factors.

A chest X-ray showed a prominent right hilum. A computed tomography (CT) scan of the thorax showed enlargement of the mediastinal lymph nodes along with nodular and linear opacification in the right upper lobe (Fig. 1). The standard Mantoux test, consisting of 2 tuberculin units Statens Serum Institute tuberculin RT23 in 0.1 ml solution injected intradermally, was strongly positive at 4 cm. Bronchoscopy results were normal. Direct microscopy with Ziehl–Neelsen staining and tuberculosis (TB) culture on sputum and bronchial washings were negative on two occasions. In view of a history of exposure to bovine TB (bTB) in the past, a presumptive diagnosis of bTB was made. The patient was commenced on anti-tuberculous therapy (ATT). He was treated with isoniazid, rifampicin and ethambutol for 2 months, followed by isoniazid and rifampicin for a further 7 months. After 9 months of treatment the patient was asymptomatic. There was radiological clearance of the changes in the right upper lobe and mediastinal adenopathy (Fig. 2).

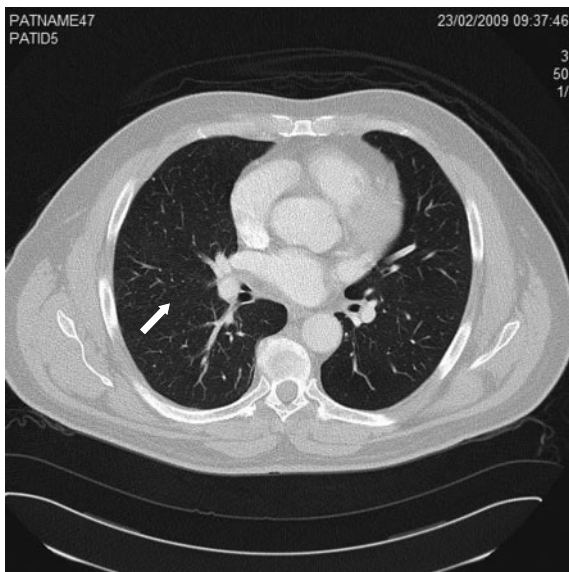
### Case 2

A 35-year-old female presented to our clinic in September 2008 with history of dry cough, chest pain, haemoptysis, night sweats and weight loss. There was a history of contact



**Fig. 1.** Case 1 before ATT. CT scan of the thorax showing parenchymal nodular and linear opacification in the right upper lobe (indicated by arrows).

with bTB at her household farm. There was no significant past medical history. She worked for a pet-food delivery service. There was no history of TB in the family. On examination, her vital signs were stable, her blood pressure 116/69 mmHg, pulse 74 beats  $\text{min}^{-1}$  and oxygen saturation 97% on ambient air. The patient otherwise appeared well. Heart sounds were normal with no added sounds.



**Fig. 2.** Case 1 after ATT. CT scan of the thorax showing that there is almost complete resolution of the previously noted pulmonary parenchymal changes (indicated by an arrow).

Respiratory examination revealed some midzone wheeze and basal crackles on the right side. The patient had a BCG (*Bacillus Calmette–Guérin*) vaccination scar on her left upper arm. She had no palpable cervical and axillary lymph nodes. Her abdomen was soft and non-tender with no organomegaly.

Laboratory examination showed an elevated platelet count of  $522 \times 10^3$  platelets  $\mu\text{l}^{-1}$  along with a raised erythrocyte sedimentation rate of  $120 \text{ mm h}^{-1}$ . The rest of the full blood count was normal. Liver function tests and renal tests were normal. Her hepatitis viral screen, including testing for hepatitis A, B and C, was all negative. Her HIV test was also negative.

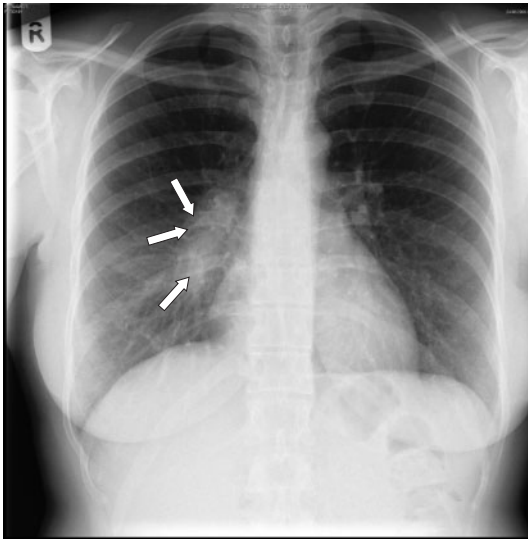
A chest X-ray showed a right hilar shadow (Fig. 3). A CT scan of her thorax confirmed bulky right hilar and mediastinal lymph nodes with segmental right middle lobe atelectasis. The standard Mantoux test consisting of an intradermal injection of 2 tuberculin units Statens Serum Institute tuberculin RT23 in 0.1 ml solution was carried out. It was strongly positive at 5 cm, with blistering. Bronchoscopy results were normal. The patient was started on ATT. Culture of sputum and bronchial washings were subsequently positive for *Mycobacterium bovis*. The isolate was resistant to isoniazid and pyrazinamide (Table 1).

The patient was initially treated with four drugs, isoniazid, rifampicin, ethambutol and levofloxacin, for 2 months, followed by isoniazid and rifampicin for 7 months. She completed a 9 month course of ATT with a full clinical response. Chest X-ray showed some persistent residual scarring in the right hilum (Fig. 4). The patient's partner was found to have a strongly positive tuberculin test and was given rifampicin prophylaxis for 6 months. He remained asymptomatic.

## Discussion

Despite the screening of cattle and the pasteurization of milk, human bTB remains a problem in Europe, including in Ireland. The incidence of human bTB in Ireland remains static. In 2006, a total of 400 cases of TB were reported out of which 5 were due to *M. bovis*. In 2007, this figure was again 5 (out of 465 reported cases). The annual number of new cases of human TB due to *M. bovis* in the UK in the period 1990–2003 varied from 17 to 50 – between 0.5 and 1.5% of cases of TB confirmed by culture (de la Rua-Domenech, 2006).

While *Mycobacterium tuberculosis* is mainly a human pathogen, *M. bovis* has a vast host range. It is the main mycobacterium responsible for TB in wild and domestic animals. In addition to cattle, important maintenance hosts of the pathogen include goats, bison, deer and badgers in Ireland and the UK, buffaloes in Africa, the moose (elk) in Canada and the common brushtail possum in New Zealand. TB in cattle is almost always acquired by inhalation and the lung is the primary focus of the disease.



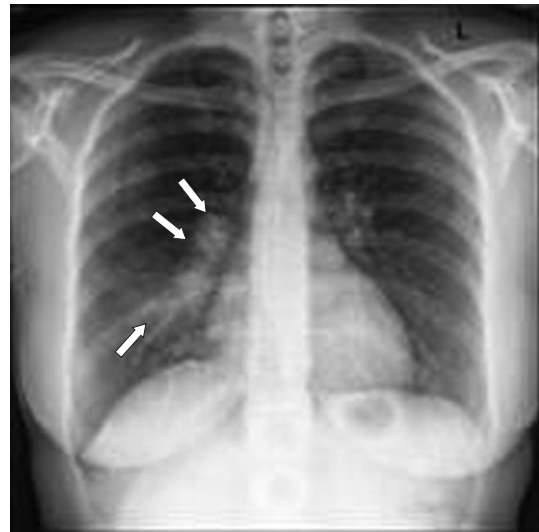**Fig. 3.** Case 2 before ATT. Chest X-ray image showing an area of increased density adjacent to right hilum suggestive of enlarged hilar lymph nodes and perihilar consolidation (indicated by arrows).

Complete elimination is not possible due to infection of cattle by wild animals and by humans with bTB.

*M. bovis* also infects humans, causing bTB through inhalation and ingestion, and by contact with mucous membranes and broken skin. Humans are spillover hosts of *M. bovis*.

As the lung is the main site of TB in cattle, farmers, veterinary surgeons and other workers in close contact with diseased animals are principally affected by the inhalation route. Workers in abattoirs and butchers are at risk of pulmonary infection by the inhalation of aerosols during the handling of diseased animal meat and carcasses.

The clinical presentation of TB due to *M. bovis* depends on the route of infection. Oral infection acquired by drinking unpasteurized milk from diseased cattle usually results in cervical or mesenteric nodes and other forms of non-pulmonary disease. Aerogenous infection from cattle or



**Fig. 4.** Case 2 after ATT. Chest X-ray image showing a reduction in the size of right hilum with some persisting prominence (indicated by arrows).

humans leads to pulmonary TB. Pulmonary bTB is clinically, radiologically and pathologically indistinguishable from TB caused by *M. tuberculosis*.

There are reported examples of cycles of transmission from animal to human, human to human and human to animal. Immunosuppressed individuals are at increased risk. This group includes people with HIV/AIDS, and those receiving immunosuppressive medications (Ayele *et al.*, 2004).

There are several reports of farm workers with bTB infecting cattle. The route of transmission of infection from farm workers to cattle is by cough spray. A case with transmission from cattle to a human and back to cattle has been described (Fritsche *et al.*, 2004). Also, transmission from cattle to human, and human to human and pet in the same household, has been described (Shrikrishna *et al.*, 2009). This illustrates the importance of all contact tracing. All human household contacts and any diseased pets should be screened. Human contact tracing includes clinical examination, chest X-ray and Mantoux test. A gamma interferon release assay (QuantiFERON-TB gold) test can be utilized in some cases. Chemoprophylaxis includes isoniazid and rifampicin for latent TB infection.

Human TB due to *M. bovis* can certainly be as severe as that due to *M. tuberculosis*. In fact recent data from San Diego, California, USA, revealed that persons with *M. bovis* were 2.55 times as likely to die during treatment than those with *M. tuberculosis* (Rodwell *et al.*, 2008).

Strains of *M. bovis* are naturally resistant to pyrazinamide. However, susceptibility to other anti-TB drugs is usually similar to that of *M. tuberculosis*. The World Health Organization 2003 guidelines on the therapy of bTB have no specific recommendations. In practice, patients are

**Table 1.** Susceptibility tests for *M. bovis* in case 2

Antituberculous drug	Sensitivity
Ethambutol	Sensitive
Isoniazid*	Resistant
Pyrazinamide	Resistant
Rifampicin	Sensitive
Streptomycin	Sensitive

\*0.1 µg isoniazid ml<sup>-1</sup>=resistant; 0.4 µg isoniazid ml<sup>-1</sup>=sensitive. These tests indicate a low level resistance to isoniazid.

treated with the standard course of anti-TB regimens, but pyrazinamide is omitted from the regimen. The American Thoracic Society recommends an initial 2 month regimen of isoniazid, rifampicin and ethambutol followed by a 7 month continuation phase of isoniazid and rifampicin.

Drug and multidrug resistance may develop and is being described. Resistance is caused by chromosomal mutations in the genes encoding drug targets. The sequential accumulation of mutations in target genes leads to the development of multidrug-resistant strains. Several diagnostic methods have been developed recently for rapid identification of these strains. These include molecular typing by RFLP and spoligotyping. The use of RFLP is convenient and reliable for the detection of *M. tuberculosis* strains but lacks sensitivity for the majority of *M. bovis* strains. A novel method called spoligotyping that is highly effective for differentiating strains of the *M. tuberculosis* complex has been developed. It offers a superior alternative when rapid identification is required and it is also more suitable for the differentiation of *M. bovis* (Blázquez *et al.*, 1997; Gutiérrez *et al.*, 1997). Outbreaks of multidrug-resistance strains involving specific strains of *M. bovis*, identified by using these techniques, have been described in care facilities for patients with HIV disease (Rivero *et al.*, 2001; Samper *et al.*, 1997). The management of such cases is the same as that of drug-resistant *M. tuberculosis* (Ahmad & Mokaddas, 2009).

The isolate from our patient in case 2 was partially resistant to isoniazid. Pulmonary TB due to multidrug-resistant *M. bovis* has been described before in immunocompetent individuals who had been in contact with patients with AIDS and *M. bovis* infection (Palenque *et al.*, 1998; Robles Ruíz *et al.*, 2002). Our patient had no such contact history.

In conclusion, *M. bovis* infection should be suspected in all at risk groups, particularly in rural areas. Close liaison between the treating physician and microbiologist is a must for a successful outcome. This is particularly relevant as *M. bovis* is naturally resistant to pyrazinamide and there is a possible emerging isoniazid resistance. All contacts should be screened, including both cattle and humans.

## References

- Ahmad, S. & Mokaddas, E. (2009). Recent advances in the diagnosis and treatment of multidrug-resistant tuberculosis. *Respir Med* **103**, 1777–1790.
- Ayele, W. Y., Neill, S. D., Zinsstag, J., Weiss, M. G. & Pavlik, I. (2004). Bovine tuberculosis: an old disease but a new threat to Africa. *Int J Tuberc Lung Dis* **8**, 924–937.
- Blázquez, J., Espinosa de los Monteros, L. E., Samper, S., Martín, C., Guerrero, A., Cobo, J., Van Embden, J., Baquero, F. & Gómez-Mampaso, E. (1997). Genetic characterization of multidrug-resistant *Mycobacterium bovis* strains from a hospital outbreak involving human immunodeficiency virus-positive patients. *J Clin Microbiol* **35**, 1390–1393.
- de la Rúa-Domenech, R. (2006). Human *Mycobacterium bovis* infection in the United Kingdom: incidence, risks, control measures and review of the zoonotic aspects of bovine tuberculosis. *Tuberculosis (Edinb)* **86**, 77–109.
- Fritsche, A., Engel, R., Bhul, D. & Zellweger, J. P. (2004). *Mycobacterium bovis* tuberculosis: from animal to man and back. *Int J Tuberc Lung Dis* **8**, 903–904.
- Gutiérrez, M., Samper, S., Jiménez, M. S., van Embden, J. D. A., Marín, J. F. G. & Martín, C. (1997). Identification by spoligotyping of a caprine genotype in *Mycobacterium bovis* strains causing human tuberculosis. *J Clin Microbiol* **35**, 3328–3330.
- Palenque, E., Villena, V., Rebollo, M. J., Jimenez, M. S. & Samper, S. (1998). Transmission of multidrug-resistant *Mycobacterium bovis* to an immunocompetent patient. *Clin Infect Dis* **26**, 995–996.
- Rivero, A., Márquez, M., Santos, J., Pinedo, A., Sánchez, M.A., Esteve, A., Samper, S. & Martín, C. (2001). High rate of tuberculosis reinfection during a nosocomial outbreak of multidrug-resistant tuberculosis caused by *Mycobacterium bovis* strain B. *Clin Infect Dis* **32**, 159–161.
- Robles Ruíz, P., Esteban, J. & Guerrero, M. L. F. (2002). Pulmonary tuberculosis due to multidrug-resistant *Mycobacterium bovis* in a healthy host. *Clin Infect Dis* **35**, 212–213.
- Rodwell, T. C., Moore, M., Moser, K. S., Brodine, S. K. & Strathdee, S. A. (2008). Tuberculosis from *Mycobacterium bovis* in binational communities, United States. *Emerg Infect Dis* **14**, 909–916.
- Samper, S., Martín, C., Pinedo, A., Rivero, A., Blázquez, J., Baquero, F., van Soolingen, D. & van Embden, J. (1997). Transmission between HIV-infected patients of multidrug-resistant tuberculosis caused by *Mycobacterium bovis*. *AIDS* **11**, 1237–1242.
- Shrikrishna, D., de la Rúa-Domenech, R., Smith, N. H., Colloff, A. & Coutts, I. (2009). Human and canine pulmonary *Mycobacterium bovis* infection in the same household: re-emergence of an old zoonotic threat? *Thorax* **64**, 89–91.